Alessio Zambello Matteo Bonetti

OZONE THERAPY

Practical Handbook

Marco Leonardi
José Baeza Noci
Massimiliano Maria Bianchi
Luigi Cirillo
Viviana Covi
Massimo Dall'Olio
Damiano Delbarba
Amato De Monte
Fabio De Santis
Tiziano Frattini
Marco Moretti
Mario Muto
Giannantonio Pellicanò
Ciro Princiotta
Gabriele Tabaracci
Adino Trivellato

FIRST EDITION

OZONE THERAPY

Practical Handbook

Alessio Zambello Matteo Bonetti

Marco Leonardi†, José Baeza Noci, Massimiliano Maria Bianchi,
Luigi Cirillo, Viviana Covi, Massimo Dall'Olio, Damiano Delbarba,
Amato De Monte, Fabio De Santis, Tiziano Frattini, Marco Moretti,
Mario Muto, Giannantonio Pellicanò, Ciro Princiotta
Gabriele Tabaracci, Adino Trivellato

FIRST EDITION

•••••

INDEX

Preface 7

Authors 8

Introduction 9

Chapter 1 11
The vertebral column
A. Zambello, M. Leonardi†, M. Bonetti, C. Princiotta, F. De Santis, M. Dall'Olio, T. Frattini, G. Pellicanò, L. Cirillo, J. Baeza Noci, D. Delbarba, M.M. Bianchi, A. Trivellato, M. Muto

1.1 Infiltration of lumbar, dorsal and cervical paravertebral muscles 13
A. Zambello, M. Bonetti, J. Baeza Noci, D. Delbarba, M.M. Bianchi, A. Trivellato

1.2 Deep lumbar intraforaminal/paravertebral infiltration via fluoroscopy or CT 19
M. Bonetti, A. Zambello

1.3 Deep cervical paravertebral infiltration via fluoroscopy or CT 25
M. Bonetti, C. Princiotta, F. De Santis, M. Dall'Olio, L. Cirillo, J. Baeza Noci, A. Zambello

1.4 Infiltration of lumbar and cervical interapophyseal joints via fluoroscopy or CT 29
M. Leonardi†, C. Princiotta, M. Bonetti, F. De Santis, M. Dall'Olio, L. Cirillo, T. Frattini, G. Pellicanò, M. Muto, A. Zambello

1.5 Cervical disc chemonucleolysis via fluoroscopy 35
M. Leonardi†, C. Princiotta, F. De Santis, M. Dall'Olio, L. Cirillo, M. Bonetti, J. Baeza Noci, A. Zambello

1.6 Lumbar disc chemonucleolysis associated with periradicular foraminal infiltration via fluoroscopy or CT 38
M. Leonardi†, M. Muto, C. Princiotta, F. De Santis, M. Dall'Olio, L. Cirillo, M. Bonetti, T. Frattini, G. Pellicanò, J. Baeza Noci, A. Zambello

Chapter 2 47
Perineural, peritendinous and intra-articular infiltration
A. Zambello, G. Tabaracci, M. Moretti, A. Trivellato, D. Delbarba

2.1 Perineural infiltration for nerve entrapment syndromes 49
A. Zambello, G. Tabaracci, M. Moretti, A. Trivellato, D. Delbarba
Median nerve entrapment syndrome (carpal tunnel syndrome)
Ulnar nerve entrapment syndrome (Guyon's canal syndrome)
Ulnar nerve entrapment syndrome (cubital canal syndrome)
Posterior tibial nerve entrapment syndrome (medial tarsal tunnel syndrome)
Sural nerve entrapment syndrome
Deep peroneal nerve entrapment syndrome (anterior tarsal tunnel syndrome)
Superficial peroneal nerve entrapment syndrome
External popliteal sciatic nerve or common peroneal nerve entrapment syndrome
Entrapment syndrome of the lateral cutaneous nerve of the thigh (Bernhardt-Roth syndrome) Interdigital nerve entrapment syndrome (Civinini-Morton neuroma)

2.2 Trapeziometacarpal articular and periarticular infiltration (rhizarthrosis) 61
A. Zambello

2.3 Peritendinous percutaneous infiltration (ozone blistering) 65
A. Zambello, M. Moretti
Infiltration of Achilles tendon
Infiltration of patellar ligament
Infiltration of supraspinatus tendon
Infiltration of infraspinatus tendon
Infiltration of subacromial bursa
Infiltration of abductor pollicis longus and extensor pollicis brevis tendons (De Quervain syndrome)
Infiltration of flexor tendons of the hand (stenosing tenosynovitis or trigger finger)
Infiltration of trochanteric region (trochanteric bursitis)
Infiltration of lateral epicondylar region (epicondylitis)
Infiltration of medial epicondylar region (medial epicondylitis)

2.4 Intra-articular infiltration of the knee 77
A. Zambello, M. Moretti
Intra-articular infiltration of the knee with lateral approach
Intra-articular infiltration of the knee with medial inferior approach

2.5 Intra-articular infiltration of hip under ultrasound guidance 81
A. Zambello, M. Moretti

2.6 Infiltration of shoulder under ultrasound guidance 85
A. Zambello, M. Moretti

Chapter 3 89
Percutaneous infiltration of oedematous panniculopathy and local adipose deposits
A. Zambello

Chapter 4 95
Systemic therapy
A. De Monte, A. Zambello, G. Tabaracci, V. Covi

4.1 Major autohemotherapy (MAH) 97
A. De Monte, G. Tabaracci, V. Covi, A. Zambello

4.2 Rectal insufflation 105
A. Zambello, G. Tabaracci, V. Covi

Chapter 5 109
Local therapies using bags, leg bags, ozone body suits, glass cups
A. Zambello, G. Tabaracci, V. Covi

Chapter 6 115
Local therapies with ozonated water
A. Zambello, G. Tabaracci, V. Covi

Chapter 7 119
Insufflation of the vaginal cavity or fistulated septic cavities
A. Zambello

Chapter 8 123
Intralesional infiltrations for the treatment of local papilloma virus (HPV) infection
A. Zambello, G. Tabaracci

Chapter 9 129
Contraindications and side effects
A. Zambello

Acknowledgements 133

Bibliography 134

Preface

Oxygen-ozonotherapy, or more simply *ozone therapy*, refers to a group of medical treatments, all very different from each other, but which share one common factor: the use of ozone gas.

Ozone is naturally present in nature, mainly in the upper layers of the atmosphere, and in the lower layers to a lesser extent. Formed by the reaction of oxygen molecules in the vicinity of high-intensity electrical discharges, such as lightning, the characteristic pungent smell of the air during summer storms is probably the most familiar example of its presence. Its molecule consists of three oxygen atoms joined by very weak chemical bonds, making it a highly reactive and unstable gas, but at the same time rich in properties used in many fields, including medicine.

The excellent disinfectant, clarifying and oxidizing capacities of ozone make it suitable for a wide variety of applications, from water purification to disinfection and use in the metallurgical and pharmaceutical industries.

Potentially harmful to health due to its high oxidizing power, ozone is used at very low concentrations when used for therapeutic purposes, administered as part of a mixture consisting mainly of oxygen (95-99%).

Living in an atmosphere rich in oxygen and its chemical compounds is not at all straightforward, living beings have developed a multitude of antioxidant mechanisms over the course of the millennia to protect against the constant danger posed by these substances. Incredible though it may seem, it is by stimulating these mechanisms that ozone exerts many of its healing and anti-inflammatory effects, a phenomenon known as the *ozone paradox*, a term coined by Professor Velio Bocci[†], whereby this potentially harmful molecule, if used appropriately and in very small doses, exerts therapeutic effects.

Over the last thirty years, the use of oxygen-ozone therapy in its various branches of application has increased tremendously, accompanied by a rise in the number of scientific articles demonstrating its effectiveness in the treatment of many diseases. Ozone is certainly not a panacea, and there are four variables – *concentration*, *volume*, *location and administration technique* – which profoundly affect the patient's response to ozone treatment in its various applications, both in good and ill-health, responses which range from a triggering an immune system response, anti-inflammatory and antibacterial actions, and boosting the peripheral circulation. The use of a gas for therapeutic purposes is a unique tool requiring extremely accurate instrumentation, thorough knowledge of methods available to the clinician, and precise treatment indications.

The development of ozone therapy techniques has taken a different course in various countries: while Italian practitioners have contributed significantly to the development of infiltrative techniques, those in Germany have focused on systemic administration using major autohemotherapy, while in Cuba the focus has been on both systemic and local techniques, with particular attention to rectal insufflations and the use of ozonated oils respectively.

The spread of ozone therapy brings with it the birth of new methods of administration: some of these are already in use, but not yet present in this first edition because they are not yet sufficiently standardised or validated by adequate scientific literature. Although a well-established practice backed up by a wealth of scientific literature, the use of ozone in dentistry is beyond the scope of this volume and has not been included.

Correct diagnosis, good patient education, and an accurate assessment of the different treatment options – including those which do not involve ozone – are the cornerstones of a good clinical outcome and perception of quality on the part of the patient.

This textbook has been a labour of love for me for many years, in which I have sought to combine my own experience with the results of the scientific literature published as time has gone on. I would like to take this opportunity to thank Matteo Bonetti and all the co-authors for their invaluable contributions, without which this text would never have come to press.

Dott. Alessio Zambello

Authors

Alessio Zambello

Specialist in anaesthesia, intensive care and pain therapy.
After working with loco-regional anaesthesia in the various surgical disciplines, he has focused his attention on non-invasive treatments for diseases affecting the spinal column. Performing ozone therapy since 2000, he has a particular interest in the side effects of ozone therapy, contributing through his articles to a review of administration techniques, reducing their side effects and improving patient comfort. In 2013, in collaboration with Professor Marco Leonardi, he wrote the guidelines of the Italian Ozone Therapy Federation (FIO).

Matteo Bonetti

Specialist in radiodiagnostics and interventional neuroradiology of the spine. Director of the Neuroradiology Department of the Clinical Institute in Brescia, Italy (*Istituto Clinico Città di Brescia*), he has been working with ozone therapy since 1993, with a particular focus on spinal techniques. Over the years, he has been committed to the research and promotion of ozone therapy in Italy and worldwide.
Author of more than 200 scientific articles on ozone therapy, he is president of the New Italian Federation of Oxygen-Ozone Therapy (New FIO) and secretary of the World Federation of Ozone Therapy (WFOOT), and a reviewer for the American Journal of Neuroradiology and Interventional Neuroradiology.

Co-authors

Marco Leonardi†
Full professor of Neuroradiology at the University of Bologna, and director of the Neuroradiology department at the Local Health Authority (AUSL) of Bologna

José Baeza Noci
Specialist in orthopaedics and traumatology, associate professor of Human Anatomy at the University of Valencia, Spain

Massimiliano Maria Bianchi
Specialist in anaesthesia, intensive care and pain therapy. Staff physician at the Circolo Hospital and the Macchi Foundation in Varese, Italy

Luigi Cirillo
Specialist in radiodiagnostics with a focus on neuroradiology. Associate professor of Neuroradiology, University of Bologna, Italy. Staff physician in diagnostic and interventional neuroradiology, Institute of Neurological Sciences of Bologna research hospital (IRCCS)

Viviana Covi
Private medical doctor, Brescia

Massimo Dall'Olio
Specialist in radiodiagnostics with a focus on neuroradiology. Staff physician in diagnostic and interventional neuroradiology, Institute of Neurological Sciences of Bologna research hospital (IRCCS)

Damiano Delbarba
Private specialist in physical and rehabilitation medicine, Domodossola, Italy

Amato De Monte
Specialist in anaesthesia, intensive care and pain therapy Specialist in pharmacology. Director of the Anaesthesia and Intensive Care Department, University Hospital of Udine, Italy

Fabio De Santis
Specialist in radiodiagnostics with a focus on diagnostic and therapeutic neuroradiology. Staff physician in diagnostic and interventional neuroradiology, Institute of Neurological Sciences of Bologna research hospital (IRCCS)

Tiziano Frattini
Specialist in radiodiagnostics. Director of the Radiology Department of the Clinical Institute Gaetano and Piera Borghi, Varese, Italy

Marco Moretti
Private sports medicine specialist, Brescia, Italy

Mario Muto
Specialist in radiodiagnostics, vascular and spinal interventional neuroradiologist. Director of the Neuroradiology Department of the Cardarelli Hospital, Napoli, Italy

Giannantonio Pellicanò
Specialist in radiodiagnostic. Specialist in neurosurgery. Neuroradiology Department of the Careggi Hospital, Firenze, Italy

Ciro Princiotta
Specialist in radiodiagnostics with a focus on neuroradiology. Staff physician in diagnostic and interventional neuroradiology, Institute of Neurological Sciences of Bologna research hospital (IRCCS)

Gabriele Tabaracci
Private orthopaedics and traumatology specialist, Brescia, Italy

Adino Trivellato
Private specialist in anaesthesia, intensive care and pain therapy, Milan, Italy

•••••

Chapter 1

The vertebral column

A. Zambello, M. Leonardi†, M. Bonetti, C. Princiotta, F. De Santis, M. Dall'Olio, T. Frattini, G. Pellicanò, L. Cirillo, J. Baeza Noci, D. Delbarba, M.M. Bianchi, A. Trivellato, M. Muto

Infiltrative methods using oxygen-ozone therapy (O_2O_3) to treat the vertebral column have been developed since 1985, thanks to the intuition of an Italian doctor, Cesare Verga. The initial rejection of ozone therapy by the medical world, however, was offset by the acceptance and appreciation of these techniques by patients seeking a solution to their health conditions without having to resort to surgery. Patients, then, were the real driving force behind the revolution brought about by ozone therapy, with word of mouth a popular form of scientific review.

The first technique described was the one defined nowadays as the classical ozone therapy technique – paravertebral infiltration – which would be joined in the years to come by techniques which increased the positive results of ozone therapy through more accurate needle placement.

Intraforaminal, deep paravertebral infiltration and intradiscal techniques followed. The pioneers were three: Giuliano Fabris, Matteo Bonetti, and Marco Leonardi. With all three techniques requiring X-ray guidance, CT and fluoroscopy became vital tools.

Guided techniques also allow positive results to be obtained in 85-90% of patients when correctly selected.

Another, no less important advantage lies in the smaller number of treatments, usually four with the intraforaminal technique, or one or two with the intradiscal technique.

Which technique is most suited to each type of disc deformation? Median hernia or intraforaminal hernia? Paramedian or extraforaminal? Contained or extruded? Over the years to come, it will be interesting to tackle this issue with scientific rigour, so as to optimize the results and speed up the healing process.

1.1 Infiltration of lumbar, dorsal and cervical paravertebral muscles

A. Zambello, M. Bonetti, J. Baeza Noci, D. Delbarba, M.M. Bianchi, A. Trivellato

THERAPEUTIC INDICATIONS

Bulging disc, herniated disc, osteoarthritis of the spine, failed back surgery syndrome (FBSS), spinal canal stenosis, foraminal stenosis

Clinical evaluation of the patient

Medical examination

- Exclude cauda syndrome
- If strength deficit is detected, take patient history/consider surgical assessment
- Evaluate or request any MRI or CT images performed in the last 12 months
- Correlate symptoms with image characteristics
- Perform or request any additional tests
- Prescribe ozone therapy
- Prescribe analgesics if needed
- Evaluate any contraindications (see page 131)

Informed consent form specific to ozone therapy

- Use specific **informed consent form**
- Have patient read and sign informed consent form

Anatomical area

- Lumbar paravertebral muscles

L1÷S1 vertebral column

- Dorsal paravertebral muscles

T1÷T12 vertebral column

- Cervical paravertebral muscles

C3÷T1 vertebral column

Number of infiltrations per single cycle

10 ÷ 15

Minimum time between infiltrations

3 days

Time between treatment cycles

Depends on symptoms and disease (alternatively follow-up treatments every 1-2-3 months)

Materials required

- Needle:

  Lumbar paravertebral muscles
  Diameter: 21 to 25 G
  Length: 35 to 100 mm depending on thickness of adipose tissue

  Dorsal paravertebral muscles
  Diameter: 21 to 25 G
  Length: 25 to 40 mm depending on thickness of adipose tissue

Infiltration of lumbar paravertebral muscles

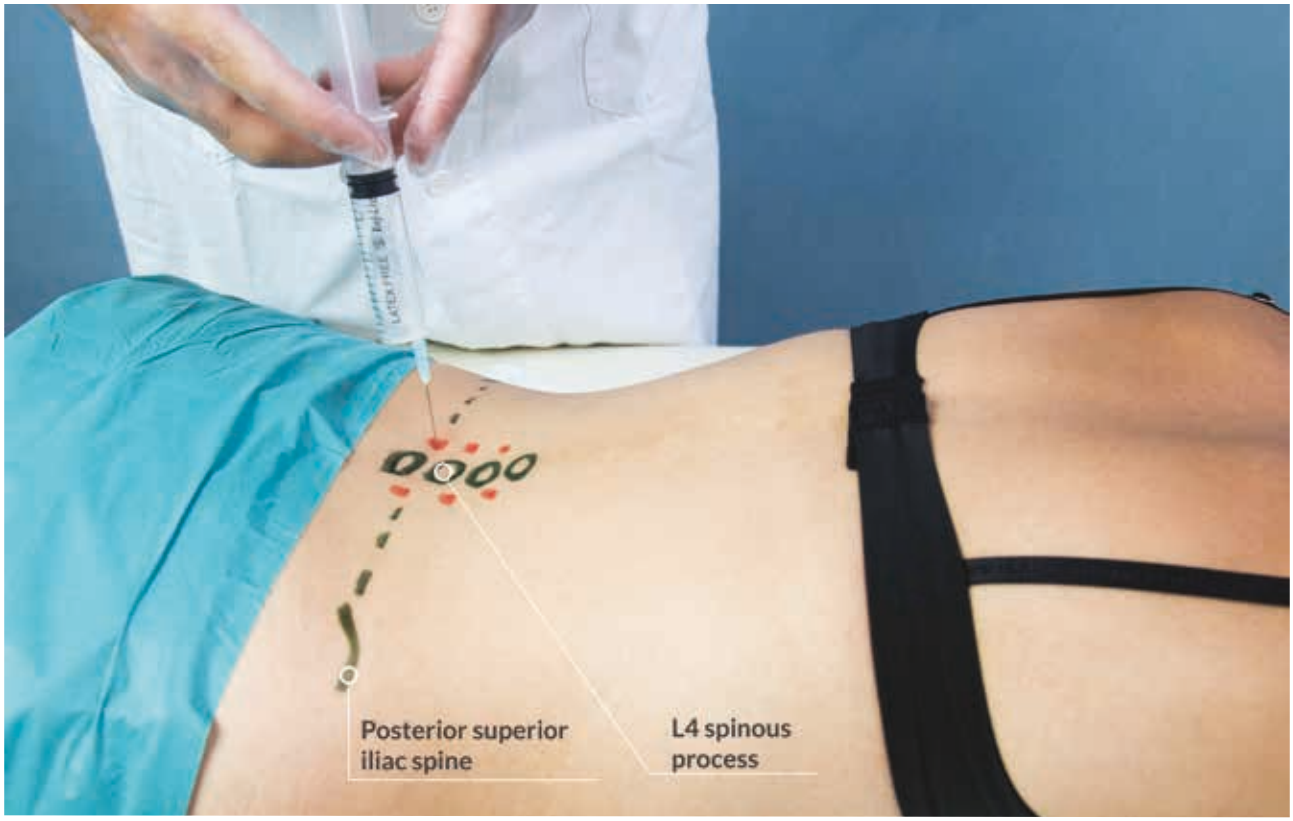

Locate the posterior superior iliac spines and the L4-L5 interspace

Inject 2-3 ml of oxygen-ozone on both sides, maintaining verbal contact with the patient

1.4 Infiltration of lumbar and cervical interapophyseal joints via fluoroscopy or CT

M. Leonardi†, C. Princiotta, M. Bonetti, F. De Santis, M. Dall'Olio, L. Cirillo, T. Frattini, G. Pellicanò, M. Muto, A. Zambello

THERAPEUTIC INDICATIONS

Interapophyseal joint disease

Clinical evaluation of the patient

Medical examination

- Evaluate or request any MRI or CT images performed in the last 6-12 months
- Correlate symptoms with image characteristics
- Perform or request any additional tests
- Prescribe ozone therapy
- Prescribe analgesics if needed
- Evaluate any contraindications (see page 131)

Informed consent form specific to ozone therapy

- Use specific **informed consent form**
- Have patient read and sign informed consent form

Anatomical area

L1÷S1 and C3÷T1 spine

Number of infiltrations per single cycle

1 ÷ 3

Minimum time between infiltrations

7 days

Time between treatment cycles

3 months

Materials required

- Needle:
  Diameter: 22 to 25 G
  Length: 35 to 90 mm depending on thickness of adipose tissue
- Antibacterial filter: 0,22 µm x 25 mm
- Disposable syringe: 10 to 30 ml in polypropylene
- For skin disinfection prior to treatment: sterile gauze, disinfectant
- For dressing following treatment: transdermal patch, gauze
- Additional materials
- Ethyl chloride spray for local anaesthesia if needed
- Cortisone for facet joint infiltration (e.g.: methylprednisolone acetate)
- Local anaesthesia for facet joint infiltration (e.g.: bupivacaine chlorhydrate)
- Requirements for materials used
- Disposable and latex free
- Disposable vinyl or nitrile gloves
- Use only CE marked medical devices
- Maintain sterility throughout the procedure
- Maximum chemical resistance to ozone oxidation

Infiltration of lumbar interapophyseal joints via fluoroscopy

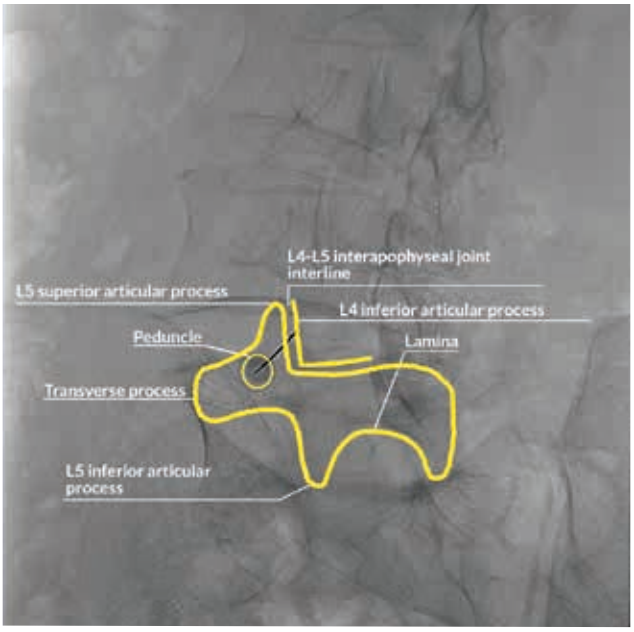

Progressively rotate the radiation beam (usually 20°-30°) to obtain an oblique projection which shows the interapophyseal joint interline with the facets parallel to each other and to the radiation beam to give the Scotty dog sign

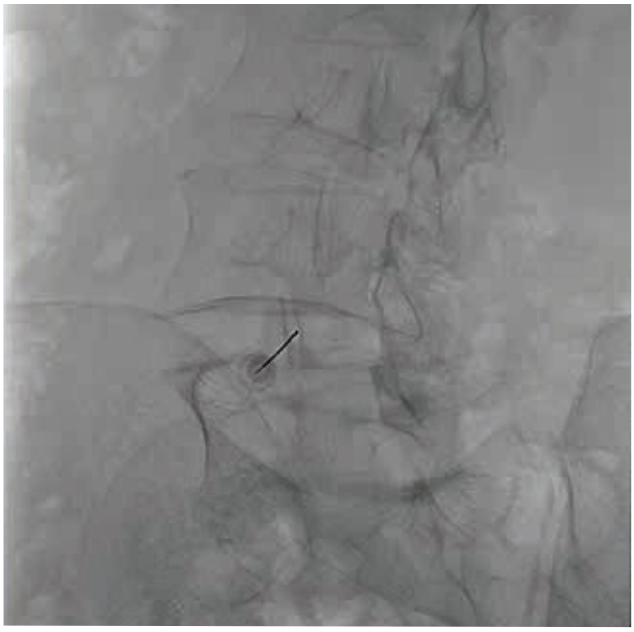

Insert the needle into the facet joint interline along the path of the incident beam

Check of needle placement in the left L4-L5 interapophyseal joint in the laterolateral projection

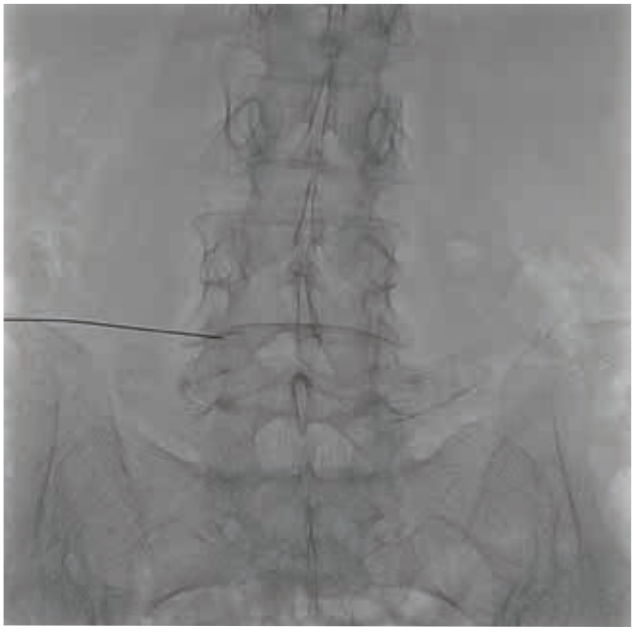

Check of needle placement in the left L4-L5 interapophyseal joint in the anteroposterior projection

•••••

1.6 Lumbar disc chemonucleolysis associated with periradicular foraminal infiltration via fluoroscopy or CT

M. Leonardi†, M. Muto, C. Princiotta, F. De Santis, M. Dall'Olio, L. Cirillo, M. Bonetti, T. Frattini, G. Pellicanò, J. Baeza Noci, A. Zambello

THERAPEUTIC INDICATIONS

Bulging disc, herniated disc, failed back surgery syndrome xxx (FBSS)

Clinical evaluation of the patient

Medical examination

- Exclude cauda syndrome
- If strength deficit is detected, take patient history/consider surgical assessment
- Evaluate or request any MRI or CT images performed in the last 6 months
- Perform or request any additional tests
- Assess laboratory test results
  - complete blood count
  - C reactive protein
  - coagulation tests: aPTT and INR
  - blood glucose
- Prescribe ozone therapy
- Prescribe drug treatment if needed
- Evaluate any contraindications (see page 131)

Informed consent form specific to ozone therapy

- Use specific **informed consent form**
- Have patient read and sign informed consent form

Anatomical area

L1-S1 spine. Multiple levels can be treated during the same session

Number of infiltrations

1, repeatable after at least 2-3 months in the case of a partial response, or subsequently in the event of clinical need due to relapse

Minimum time between infiltrations

2-3 months

Time between treatment cycles

2 ÷ 3 months

Materials required

- Needle:
  Diameter: 22 G
  Length: 150 or 200 mm depending on the level to be treated and patient build
- Antibacterial filter: 0.22 µm x 25 mm
- Disposable syringe: da 20 ml in Polipropilene
- For skin disinfection prior to treatment: sterile gauze, disinfectant chirurgico a base di iodopovidone
- For dressing following treatment: transdermal patch, gauze

Lumbar disc chemonucleolysis associated with periradicular foraminal infiltration via fluoroscopy

Since access is made on the affected side, the patient will be lying on the opposite side to that to be treated

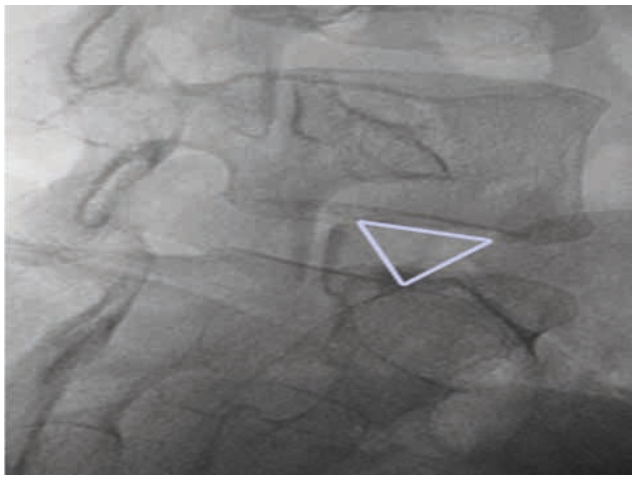

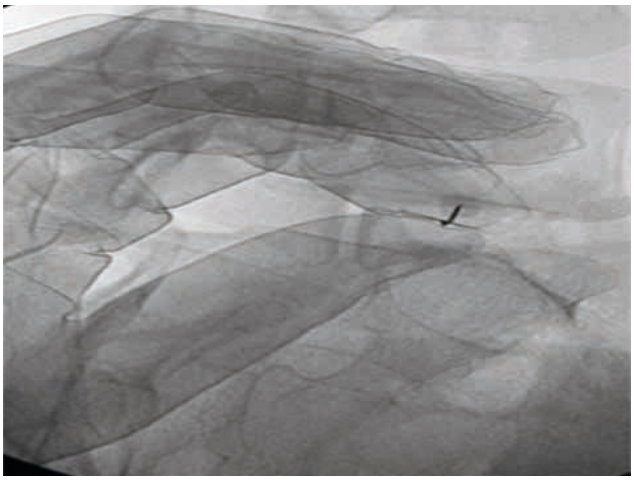

L5-S1 Moving the C-arm craniocaudally gives a triangular area of access to the disc, delimited superiorly by the inferior edge of L5, posteriorly by the anterior profile of the superior articular process of S1, and anteriorly by the superior edge of the homolateral iliac wing

•••••

Chapter 2

Perineural, peritendinous and intra-articular infiltration

A. Zambello, G. Tabaracci, M. Moretti, A. Trivellato, D. Delbarba

Peritendinous and intra-articular infiltration techniques are based on the local anti-inflammatory action of the O_2O_3 oxygen-ozone mixture. To put it very simply, ozone can be used in place of cortisone, since it causes no local or systemic side effects. Ozone, however, differs in the delay in its onset of action compared to cortisone: while cortisone acts relatively quickly, ozone takes two to three weeks and repeated treatments to develop its action. Ensuring that the patient is given adequate information is key to improving the success of treatment.
Ultrasound guidance permits optimisation of the administration technique and is vital for the infiltration of deeper areas such as the hip.

2.1 Perineural infiltration for nerve entrapment syndromes

A. Zambello, G. Tabaracci, M. Moretti, A. Trivellato, D. Delbarba

THERAPEUTIC INDICATIONS

Entrapment syndromes: median nerve (carpal tunnel syndrome), ulnar nerve (Guyon's canal syndrome), posterior tibial nerve (medial tarsal tunnel syndrome), sural nerve, deep peroneal nerve (anterior tarsal tunnel syndrome), superficial peroneal nerve, external popliteal sciatic nerve, lateral cutaneous femoral nerve (meralgia paresthetica), interdigital nerve (Morton's neuroma)

Clinical evaluation of the patient

Medical examination

- If strength deficit is detected, take patient history/consider surgical assessment
- Evaluate or request any EMG tests performed in the last 6 months
- Correlate symptoms with EMG test results
- Perform or request any additional tests
- Prescribe ozone therapy
- Prescribe analgesics if needed
- Evaluate any contraindications (see page 131)

Informed consent form specific to ozone therapy

- Use specific **informed consent form**
- Have patient read and sign informed consent form

Anatomical area

Upper and lower limbs

Number of infiltrations per single cycle

5 ÷ 12

Minimum time between infiltrations

3 days

Time between treatment cycles

Depending on symptoms (alternatively, 3 follow-up infiltrations at monthly or bi-monthly intervals)

Materials required

- Needle:
  Diameter: 23 to 27 G
  Length: 13 to 35 mm depending on thickness of subcutaneous tissue
- Antibacterial filter: 0.22 µm x 25 mm
- Disposable syringe: 10 to 20 ml in polypropylene
- For skin disinfection prior to treatment: sterile cotton balls, sterile gauze, disinfectant
- For dressing following treatment: transdermal patch, gauze

Additional materials

Ethyl chloride spray for local anaesthesia if needed

Requirements for materials used

- Disposable and latex free
- Disposable vinyl or nitrile gloves
- Use only CE marked medical devices
- Maintain sterility throughout the procedure
- Maximum chemical resistance to ozone oxidation

Method

1) Put the patient on the bed in a supine or seated position.
2) Decide the O_2O_3 concentration to be generated (see point 12) and set the MOG accordingly.
3) Fit the ozone-resistant antibacterial filter on to the MOG valve or sampling syringe.
4) Thoroughly disinfect the injection site and surrounding area.
5) Locate the injection site via the appropriate anatomical reference points and insert the needle so that it pierces the skin and the tip is in proximity to the nerve. If needle placement causes paraesthesia, withdraw the needle by 1-2 mm to prevent injection into the nerve.
6) Draw back the plunger and aspirate to ensure the tip of the needle is not in a vein or artery. If there is blood in the syringe, change injection site and aspirate once more.
7) Fill the syringe with the desired O_2O_3 concentration from the MOG through the ozone-resistant antibacterial filter.
8) Remove the antibacterial filter and connect the needle to the syringe.
9) Administer the O_2O_3, observing the following rules:
   - Administer slowly to minimise pain to the patient
   - In the case of high administration pressures, withdraw the tip of the needle by 1-3 mm, being sure to aspirate once more as described in point 6
   - Limit the injected quantities of O_2O_3 to the recommended doses (see points 10 and 11)
10) Volumes of O_2O_3 to be injected: 1.5-5 ml per single infiltration.
11) Maximum total volume to be injected per session: 5-15 ml, depending on the injection site.
12) O_2O_3 concentration: 7-12 µg/ml.
13) Dress the treated area.
14) Leave the patient on the bed for about 1 minute.
15) Ask the patient to sit up, ensuring they do not feel faint or dizzy.
16) Ask the patient to stand, ensuring they do not feel faint or dizzy.
17) Monitor the patient throughout the procedure for any side effects.

Median nerve entrapment syndrome (carpal tunnel syndrome)

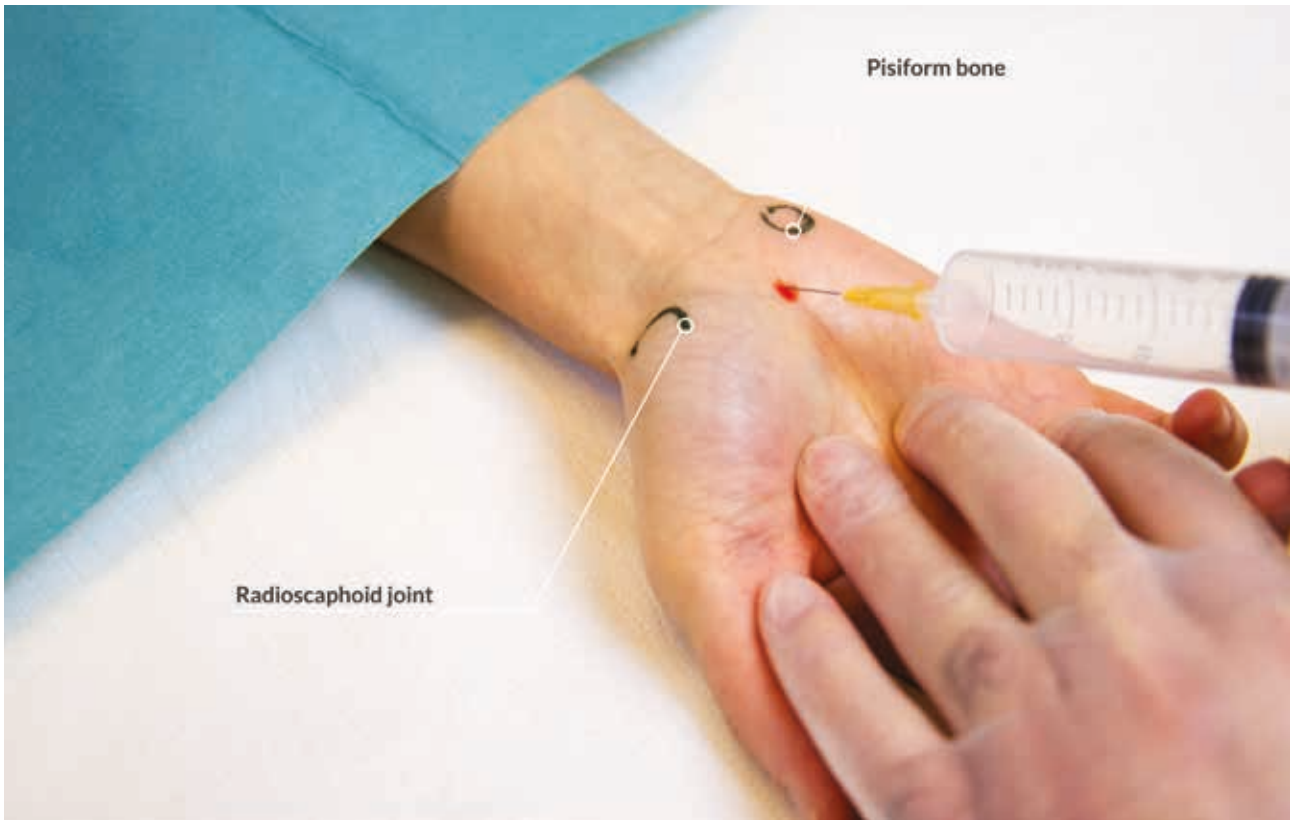

Insert the needle into the skin crease approximately two centimetres distally from the interline between the proximal margin of the thenar eminence (radioscaphoid joint) and the proximal margin of the hypothenar eminence (pisiform bone

Gently inject approximately 5 ml of oxygen-ozone, progressively withdrawing the needle

•••••

2.3 Peritendinous percutaneous infiltration (ozone blistering)

A. Zambello, M. Moretti

THERAPEUTIC INDICATIONS

Tendinitis, tendinosis, stenosing tenosynovitis (trigger finger)

Clinical evaluation of the patient

Medical examination

- Correlate symptoms with ultrasound test results
- Perform or request any additional tests: RM
- Prescribe ozone therapy
- Prescribe analgesics if needed
- Evaluate any contraindications (see page 131)

Informed consent form specific to ozone therapy

- Use specific **informed consent form**
- Have patient read and sign informed consent form

Anatomical area

Achilles tendon, patellar ligament, abductor pollicis longus and abductor pollicis brevis muscles, supraspinatus tendon, infraspinatus tendon, tendons with insertion on medial epicondyle of the humerus, other tendons

Number of infiltrations per single cycle

10 ÷ 12

Minimum time between infiltrations

3 days

Time between treatment cycles

Depends on symptoms

Materials required

- Needle:
  Diameter: 23 to 30 G
  Length: 13 to 50 mm depending on thickness of subcutaneous tissue
- Antibacterial filter: 0,22 µm x 25 mm
- Disposable syringe: 10 to 20 ml in polypropylene
- For skin disinfection prior to treatment: cotton balls, sterile gauze, disinfectant
- For dressing following treatment: transdermal patch, gauze

Additional materials

Ethyl chloride spray for local anaesthesia if needed

Requirements for materials used

- Disposable and latex free
- Disposable vinyl or nitrile gloves
- Use only CE marked medical devices

•••••

Infiltration of Achilles tendon

Put the patient in the prone position. Insert the needle parallel to the path of the tendon

Inject 2-3 ml of oxygen-ozone at each point, for a total volume of 15-20 ml

•••••

Infiltration of supraspinatus tendon

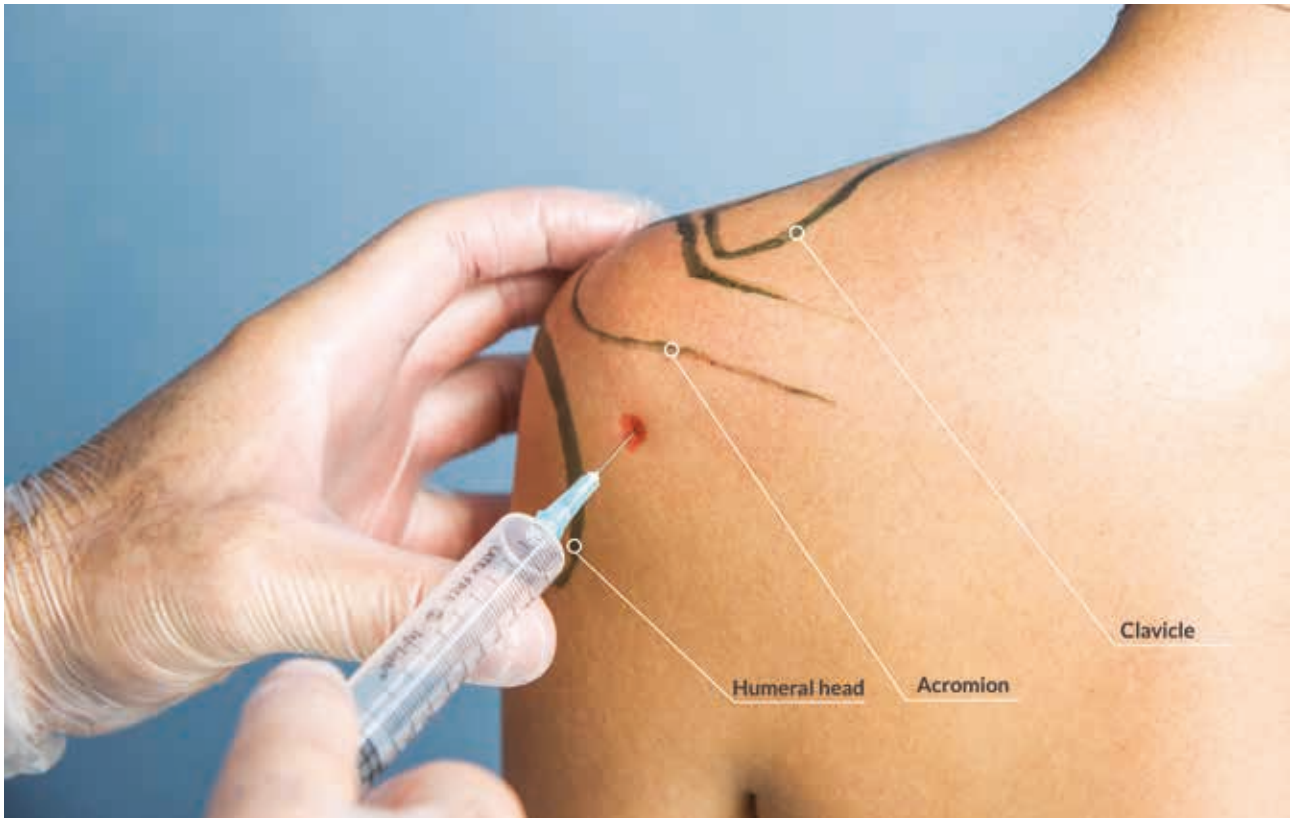

Put the patient in a seated position and insert the needle perpendicular to the skin plane

Infiltration of infraspinatus tendon

Put the patient in a seated position. Insert the needle perpendicular to the skin plane and inject 4-5 ml of oxygen-ozone at a depth of 2-3 cm (the depth depends on the anatomy of the individual patient)

•••••

Intra-articular infiltration of the knee with lateral approach

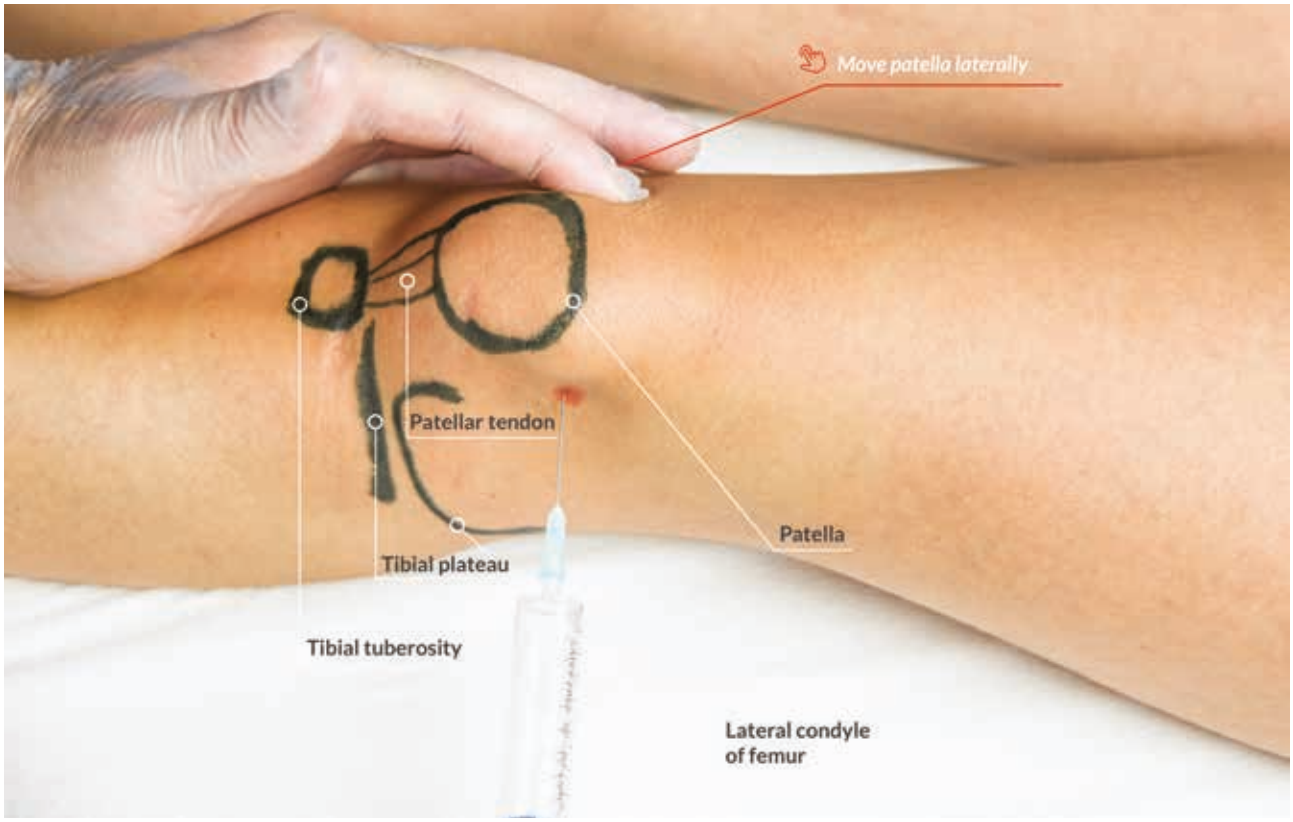

Move the patella laterally with the non-dominant hand and insert the needle into the skin pouch between the patella and the femur

Exclude the presence of effusion (perform arthrocentesis if necessary), then administer 10-12 ml of oxygen-ozone

•••••

Chapter 3

Percutaneous infiltration of oedematous panniculopathy and local adipose deposits

A. Zambello

Probably the most common technique, despite relatively little published literature. Close attention must be paid to the tiny volumes to be injected into each individual site.

Percutaneous infiltration of oedematous panniculopathy and local adipose deposits

A. Zambello

THERAPEUTIC INDICATIONS

Oedematous panniculopathy

Clinical evaluation of the patient

Medical examination

- Perform or request any additional tests
- Prescribe ozone therapy
- Evaluate any contraindications (see page 131)

Informed consent form specific to ozone therapy

- Use **specific informed consent form**
- Have patient read and sign informed consent form

Anatomical area

- Lower limbs
- Upper limbs
- Periumbilical region

Number of infiltrations per single cycle

10 ÷ 15

Minimum time between infiltrations

3 days

Time between treatment cycles

- 6-12 months
- Follow-up sessions every 1-2 months if necessary

Materials required

- Needle:
  Diameter: 25-27-30 G
  Length: 5 to 15 mm depending on thickness of subcutaneous tissue
- Antibacterial filter: 0.22 µm x 25 mm
- Disposable syringe: 30 to 50 ml in polypropylene
- For skin disinfection prior to treatment: cotton balls, disinfectant
- For dressing following treatment: transdermal patch, gauze
- Infiltration depth: 3-5 mm

Additional materials

- Massage cream

Requirements for materials used

- Disposable and latex free
- Disposable vinyl or nitrile gloves
- Use only CE marked medical devices
- Maintain sterility throughout the procedure
- Maximum chemical resistance to ozone oxidation

•••••

Percutaneous infiltration of oedematous panniculopathy and local adipose deposits

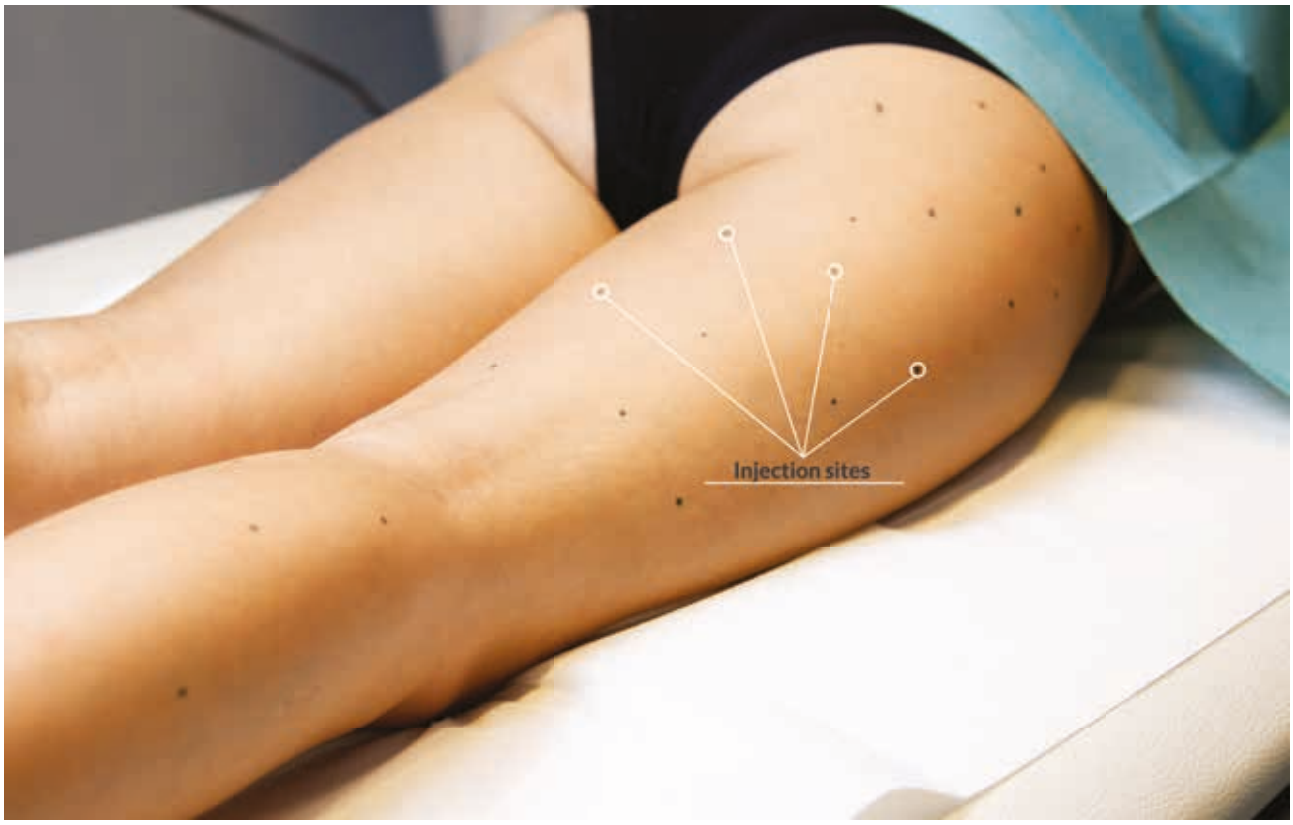

Distribute the injection sites evenly over the treatment area

Inject 2-3 ml of oxygen-ozone slowly and continuously into each site

•••••

Chapter 5

Local therapies using bags, leg bags, ozone body suits, glass cups

A. Zambello, G. Tabaracci, V. Covi

Topical ozone has been used for around a hundred years, initially being used to treat soldiers' wounds during the First World War. Still today, it is most widely used to treat peripheral vasculopathies, infected wounds and fistulas.

The World Health Organisation (WHO) considers this technique to be effective against Buruli ulcers, a disease endemic to central Africa caused by Mycobacterium ulcerans.

Local therapies using bags, leg bags, ozone body suits, glass cups

Spray the wound with ozonated water or normal saline before exposing it to the ozone

To prevent the leakage of ozone into the room, do not exceed the inflation pressure of the bag

The first ever practical handbook dedicated to the world of ozone therapy, written by **leading experts with thirty years' experience** and a history of scientific papers on international journals.
An essential book for doctors examining this fascinating subject, which is gaining increasing popularity among patients due to its wide range of application and its benefits through minimally invasive procedures.
The practical handbook is easy to consult and simple to use, thanks to the 94 original photographs with descriptions of anatomical reference points and the materials required to be able to safely carry out the various techniques described in complete autonomy.